



PRESENTING CLINICAL SIGNS

DATE History: Adopted from shelter and reportedly heartworm positive at that time. Started on doxycycline and heartworm prevention on 1/31/22. ELISA Dirocheck test is negative, and no microfilaria are seen on a slide. Retesting for worms with pre/post-heat treated sample recommended in 6 weeks.

2/14/22

ECHOCARDIOGRAPHIC FINDINGS

2D, M-mode, and Doppler study.

PERFORMED BY:
Holly Burleson, LVT

Left atrial size is normal. The mitral valve is normal. Left ventricular dimensions are normal. Left ventricular systolic function is mildly hyperdynamic. The aorta and aortic valve are normal. Right atrial and right ventricular dimensions are normal. The tricuspid valve appears normal, though trace tricuspid regurgitation is present. The pulmonary artery and pulmonic valve are normal. No shunting lesions are visualized. No heartworms are visualized. No pericardial effusion or cardiac masses are seen.

INTERPRETED BY
Keith Blass, DVM,
MS, DACVIM
(Cardiology)

PATIENT
LA - 34.6 mm
LVIDd - 33.4 mm
LVIDs - 19.2 mm
FS - 42.5%
LVOT - 1.02 m/s
RVOT - 0.75 m/s

Demetri Velazquez

ASSESSMENT/RECOMMENDATIONS

Canine
Normal echocardiogram

BREED
Boxer Mix
This examination demonstrates no abnormalities, as trace tricuspid regurgitation can be considered as normal physiologic variant. While no worms were visualized in Demetri's heart or proximal pulmonary arteries, the presence of heartworm disease cannot be ruled out, as worms being growing in the peripheral pulmonary arteries and only migrate to the proximal pulmonary arteries and right heart chambers where they are visible echocardiographically when worm burdens are high; therefore, the presence of a low-worm burden infection cannot be ruled out.

SEX Retesting for heartworm antigen again as previously recommended is warranted.

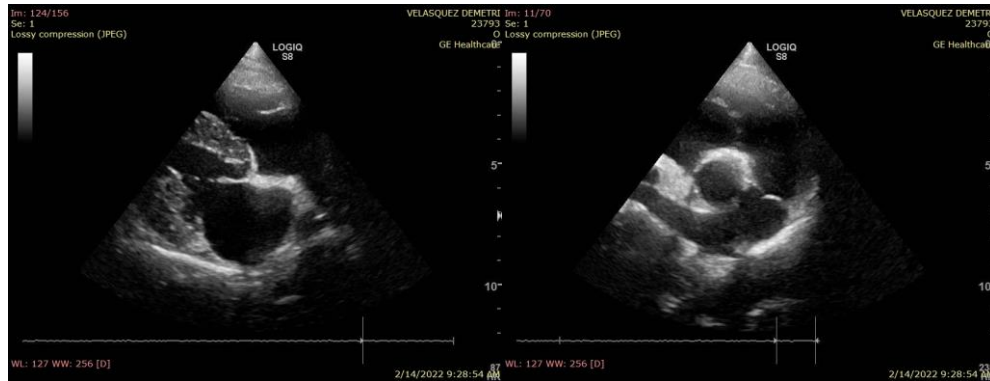
MN Should Demetri's recheck antigen test be positive, therapy with heartworm adulticide therapy would be warranted, as would strict exercise restriction throughout the course of therapy.

AGE A recheck echocardiogram is recommended if new physical exam and/or clinical abnormalities suggestive of cardiac dysfunction develop.

2 y

WEIGHT
49.1 lb

HOSPITAL NAME
All Pets Medical
Center



REFERRING VET The information and recommendations provided are based on the images presented by the

Dr. Rupley



DATE referring veterinarian. No evaluation can be communicated regarding pathology that was not visible in the image/video clips provided.

2/14/22 Thank you for this referral. If the clinical or image interpretation does not parallel your findings or if I can be of any further assistance please contact me.

PERFORMED BY: Keith Blass, DVM, MS, DACVIM (Cardiology)
KeithBlass@gmail.com
Holly Burleson, LVT 631-804-5754

INTERPRETED BY
Keith Blass, DVM,
MS, DACVIM
(Cardiology)

PATIENT
Demetri Velazquez

SPECIES
Canine

BREED
Boxer Mix

SEX
MN

AGE
2 y

WEIGHT
49.1 lb

HOSPITAL NAME
All Pets Medical
Center

REFERRING VET
Dr. Rupley